Partner Veterinary
EMERGENCY & SPECIALTY CENTER

Canine Melanoma- An Update on Immunotherapy

Kyle Renaldo DVM, MS, DACVIM (Oncology)



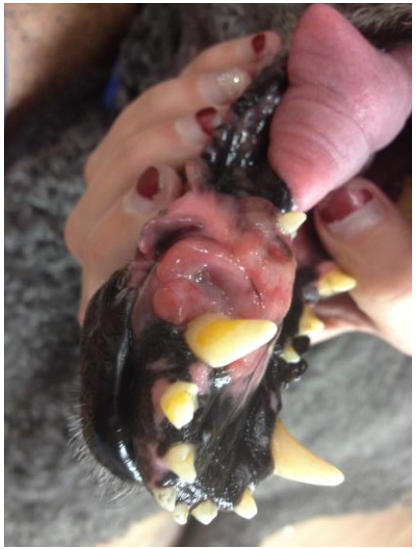



Outline

- Introduction to Melanoma
- Biologic Behavior and Prognostic Factors
- Stages of Melanoma
- Local Treatment Options
  - A Focus on Regional Lymph Nodes with Oral Melanoma
- Immunotherapy
  - The Melanoma Vaccine
  - Gilvetmab



Introduction to Melanoma

- Melanoma arises from melanocytes, which are cells that generate pigment through the melanosome by a number of melanosomal glycoproteins
- UV-associated melanoma is rare in dogs due to the presence of a hair coat
- The most common oral malignancy in dogs
  - Breeds: Scottish terriers, Golden retrievers, Poodles, Dachshunds
  - Gingiva, lips, tongue, and hard palate (in order of most common location)
- Primary factors for biological behavior: Location, size, stage, and histologic parameters (i.e. mitotic index, Ki67, degree of pigmentation)

Biologic Behavior and Prognostic Factors

- Anatomic location is highly predictive of local invasiveness and metastatic propensity
  - Melanomas of haired skin not in proximity to mucosal margins often behave in a benign fashion (~85% benign)
  - Oral and/or mucosal melanoma has been considered an extremely malignant tumor with a high degree of local invasiveness and high metastatic propensity (Goldschmidt 1985, Smith et al. 2002)
  - Anatomic sites of intermediate prognostic significance between the generally benign-acting haired-skin and the often malignant and metastatic oral/mucosal melanomas include the digit and footpad
    - Metastasis of digital melanomas present at diagnosis in 30-40% of patients (Marino et al. 1995)

Prognostic markers for canine melanocytic neoplasms: a comparative review of the literature and goals for future investigation. Smedley et al. 2011.

Location	Oral/Lip Melanocytic Neoplasms		Cutaneous/Digit Melanocytic Neoplasms
Distant metastasis	Poor prognosis		Poor prognosis
Lymphatic invasion	Poor prognosis		Poor prognosis[a]
Mitotic index	10 consecutive fields starting in area w/highest mitotic activity		10 random fields
	Avoid areas of ulceration for both methods		
	< 4/10 hpf	Favorable prognosis	< 3/10 hpf
	≥ 4/10 hpf	Poor prognosis	≥ 3/10 hpf
Nuclear atypia[b]	% atypical nuclei in 200 cells counted		Subjective assessment
	< 30%	Favorable prognosis	< 20%
	≥ 30%	Poor prognosis	≥ 20%

Prognostic markers for canine melanocytic neoplasms: a comparative review of the literature and goals for future investigation. Smedley et al. 2011.

Location	Oral/Lip Melanocytic Neoplasms		Cutaneous/Digit Melanocytic Neoplasms
Degree of pigmentation	Subjective assessment		
	% Pigmented cells		Scale 0 (no pigment) to 2 (high pigment)
	≥ 50%	Favorable prognosis	2
	< 50%	Uncertain prognosis	0 to 1
Presence of ulceration	No prognostic significance		Poor prognosis
Level of infiltration/invasion	Shallow w/no bone lysis	Favorable prognosis	Limited to dermis
	Deep w/possible bone lysis	Poor prognosis	Extends beyond dermis
Ki67 index	Average number of positive nuclei per grid (5 hpf grid areas counted)		% of positive nuclei in 500 cells counted
	Avoid areas of ulceration and inflammation and assess highest staining areas for both methods		
	< 19.5	Favorable prognosis	< 15%
	≥ 19.5	Poor prognosis	≥ 15%

Stages of Melanoma

Box 19-1 **Traditional World Health Organization (WHO) TNM-Based Staging Scheme for Dogs with Oral Melanoma**

T: Primary Tumor

T1	Tumor ≤2 cm in diameter
T2	Tumor 2-4 cm in diameter
T3	Tumor >4 cm in diameter

N: Regional Lymph Nodes

N0	No evidence of regional node involvement
N1	Histologic/cytologic evidence of regional node involvement
N2	Fixed nodes

M: Distant Metastasis

M0	No evidence of distant metastasis
M1	Evidence of distant metastasis

Stage I = T1 N0 M0
Stage II = T2 N0 M0
Stage III = T2 N1 M0 or T3 N0 M0
Stage IV = Any T, any N, and M1

- Median survival times for dogs with oral melanoma treated with surgery are ~17-18 months, ~5-6 months, and 3 months for Stage I, II, and III disease, respectively (Macewen et al. 1986)

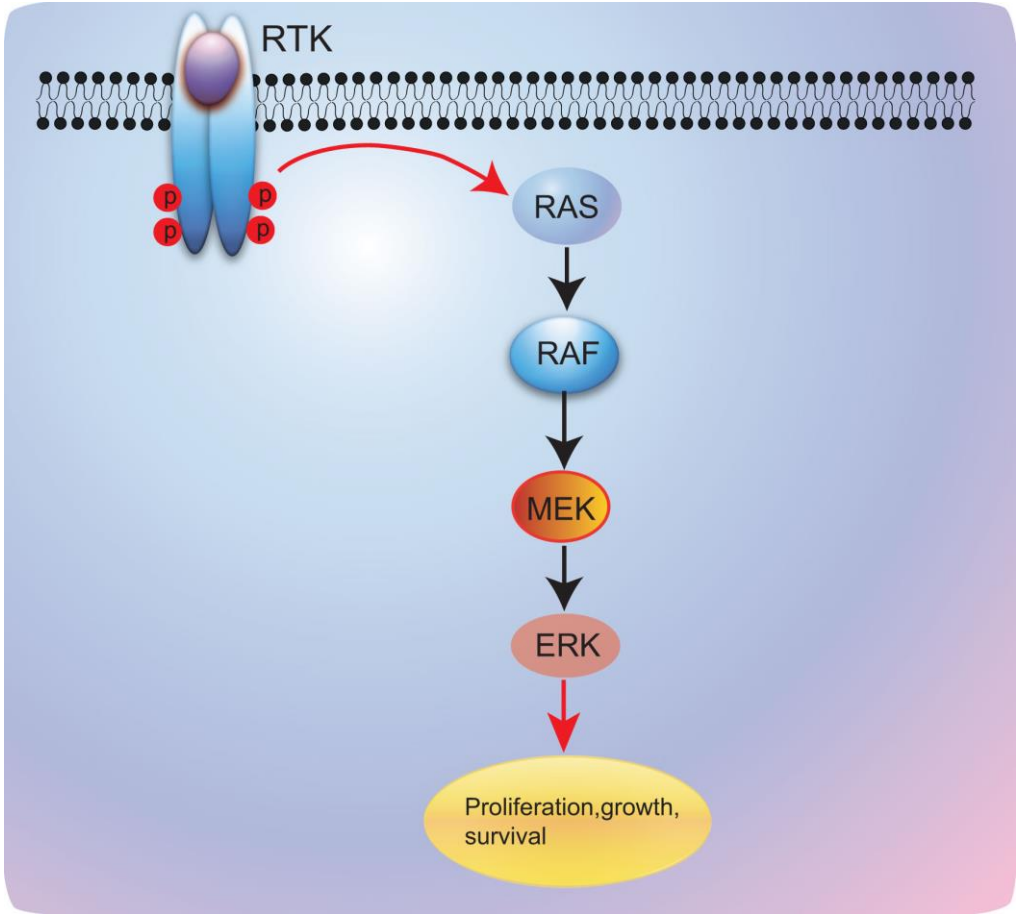
RTK
P
P
P
P
RAS
RAF
MEK
ERK
Proliferation,growth,
survival

Local Treatment: Surgery

- Tumors in the caudal aspect of the oral cavity are often large at the time of diagnosis relative to rostral tumors
- Benign cutaneous tumors are typically complete excised with 1-cm skin margins and ideally one fascial plane deep
- Partial mandibulectomy or maxillectomy are often required for complete excision of oral melanomas arising from the gingiva or other oral mucosa in close proximity to bone
  - Advanced imaging (CT scan) is critical for assessment of tumor extent and potential bone involvement
  - Dogs with tumor cells extending to the peripheral margin were 3.6 times more likely to die from tumor-related causes; Dogs with tumors caudal to premolar number three (PM3) were 4.3 times more likely to die from tumor-related causes

Local Treatment: Surgery

- Local recurrence rates vary from 22% following mandibulectomy to 48% with maxillectomy
- Median survival time for dogs treated with surgery alone is 150-318 days, 1-year survival rate 35%
- If an oral tumor is debulked for biopsy and diagnosis, please take pictures for the record

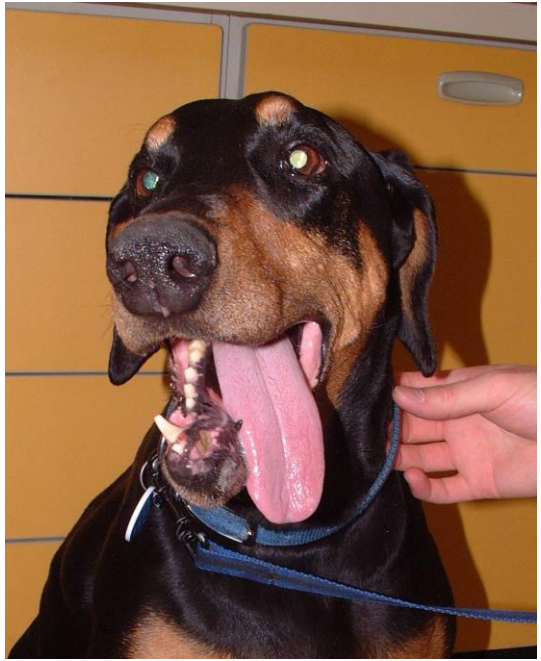

Table 3. Sensitivities and Specificities of 9 Antibodies and an Immunodiagnostic Cocktail for Detection of Canine Oral/Lip Amelanotic a Neoplasm Versus Soft Tissue Spindle Cell Sarcoma: In Percentages

Antibody	Sensitivity	Specificity
Melan-A	81.60	100
PNL2	89.80	100
Tyrosinase-related protein 1	55.10	100
Tyrosinase-related protein 2	79.60	100
Microphthalmia transcription factor, nuclear	91.80	20
S-100	81.60	20
HMB-45	12.20	100
Tyrosinase	6.10	100
Tyrosine hydroxylase	6.10	100
Melanocytic cocktail	93.90	100

Immunohistochemical diagnosis of canine oral amelanotic melanocytic neoplasms. Smedley et al. 2021.

Association between lymph node size and metastasis in dogs with oral malignant melanoma: 100 cases (1987-2001), Williams and Packer 2003

- Forty-seven (47%) dogs, of which 23 (49%) had enlarged mandibular lymph nodes, had no cytologic or histologic evidence of metastasis
- Of 53 (53%) dogs with cytologic or histologic evidence of mandibular lymph node metastasis, 37 (70%) had enlarged mandibular lymph nodes, and 16 (30%) had mandibular lymph nodes of normal size
- Sensitivity and specificity of lymph node size as a predictor of metastasis were 70 and 51%, respectively, and the positive and negative predictive values were 62 and 60%, respectively

Case Example: Ridge

- 4 year old MC Labrador Retriever
- 1/29/2025: Dental prophylaxis for fractured right maxillary 4th premolar tooth (108)
  - ~3 mm pigmented lesion noted within buccal mucosa or right lip commissure
  - Histopathology: Narrowly excised melanoma (margin 1.8 mm), MI 0 per 10 hpf
- 2/26/2025: Surgical scar revision with submandibular lymph node extirpation



Case Example: Ridge

- Histopathology:
  - Right lip commissure: Mucosa fibrosis and hyperplasia with submucosal aggregated melanocytes
  - Right mandibular lymph node: Metastatic melanoma
  - Left mandibular lymph node: Metastatic melanoma
- Completed Melanoma vaccine series 4/30/2025



Local Treatment: Radiation Therapy

- Melanoma is thought to be a radioresistant tumor type often necessitating a higher dose in each fraction to achieve local control
  - Hypofractionated protocol: 8 Gray x 4 treatments (32 gray total dose)
- Most studies reported using at least a 2-cm margin around the tumor bed or surgical incision site
- Reported range of partial and complete responses to radiation therapy are 25-31% and 51-69%, respectively, yielding an overall response rate of 82-94% (Bateman et al. 1994, Proulx et al. 2003)
- Progressive-free survival ranges from 5-7.9 months, Median survival times range from 5.9-11.9 months
- Several studies did not find a benefit in survival time with the introduction of chemotherapy with radiation therapy (Proulx et al. 2003, Murphy et al. 2005)

Case Example: Norma

- 9 year old FS Bernese Mountain Dog
- AAVEC 6/26/2024: Bleeding oral mass associated with right rostral mandible
- Biopsy of mass 7/3/2024: Melanoma, MI 64 per 10 hpf, pulmonary nodule in left caudal lung lobe on CT scan
- Rapid, exponential growth across rostral mandible under tongue- no surgical option



Case Example: Norma

- Hypofractionated radiation therapy (8 Gray x 4 treatments) and Melanoma vaccine series 8/6/2024

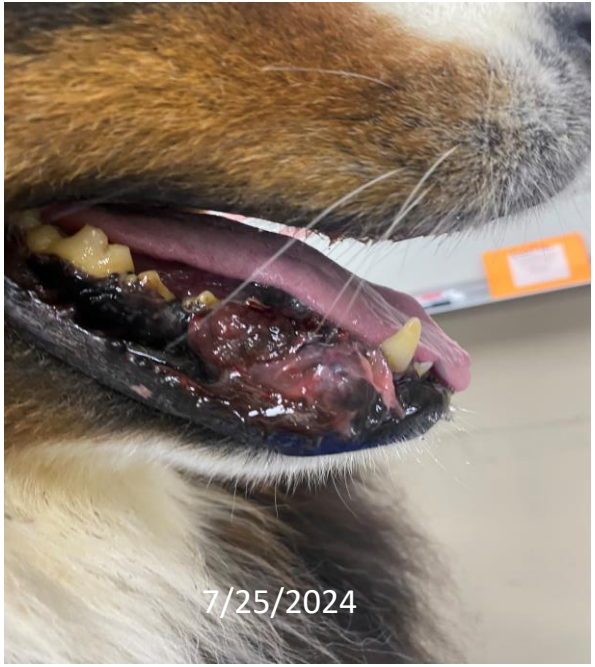



Case Example: Norma





6-months post-RT



6-months post-RT



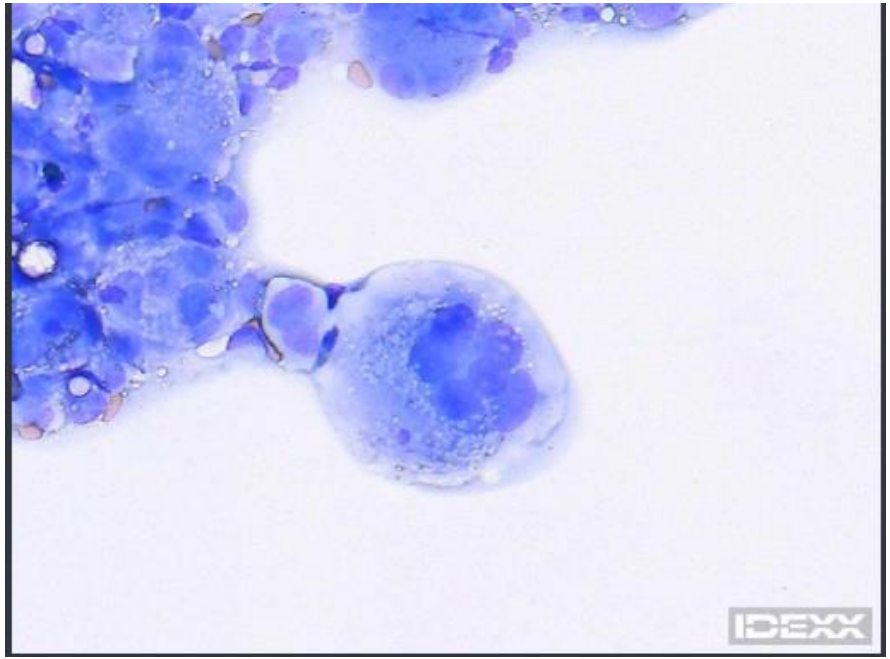

Safety and efficacy of a xenogeneic DNA vaccine encoding for human tyrosinase as adjunctive treatment for oral malignant melanoma in dogs following surgical excision of the primary tumor. Grosenbaugh et al. 2011

- Vaccine containing plasmid DNA with an insert encoding human tyrosinase
- 111 dogs (58 prospectively enrolled in a multicenter clinical trial and 53 historical controls) with stage II or III oral MM (modified World Health Organization staging scale, I to IV) in which locoregional disease control was achieved
- 58 dogs received an initial series of 4 injections of huTyr vaccine (102 µg of DNA/injection) administered transdermally by use of a needle-free IM vaccination device
- Median survival time for historical controls in the study was 324 days vs. 25th percentiles of survival times of vaccinates was 464 days
- Median survival time could not be determined for vaccinates because < 50% died of malignant melanoma before the end of the observation period

Xenogeneic murine tyrosinase DNA vaccine for malignant melanoma of the digit of dogs. Manley et al. 2011

- Fifty-eight dogs with digit malignant melanoma treated at the Animal Medical Center between 2004 and 2007
- Overall median survival time for dogs treated with loco-regional control and xenogeneic DNA vaccine was 476 days with a 1-year survival rate of 63%
- Median survival time for dogs presenting with metastasis was 105 days versus 533 days for dogs presenting without metastasis

Melanoma vaccine series

- Approved by USDA in 2009- not as rigorous clinical testing as FDA approval
- Needleless injection into inner thigh every 2 weeks for 4 total treatments
  - Labelled to administered by only veterinary oncologists
  - Minimal side effects



Use of adjuvant carboplatin for treatment of dogs with oral malignant melanoma following surgical excision. Dank et al. 2014

- Retrospective study evaluating adjuvant Carboplatin chemotherapy (with or without radiation therapy) in 17 dogs with malignant oral melanoma following surgical resection
- The overall median progression-free survival for all dogs was 259 days [95% confidence interval (CI95), 119 – 399 days]
- The first progression-free survival event was local recurrence in seven dogs (41%) and metastases in seven dogs (41%)
- The median overall survival for all dogs was 440 days (CI95, 247 – 633 days)
- Overall response rate against melanoma: 28%

Case Example: Indiana

- 11 year old FS Labrador Retriever mix
- Debulkment from left rostral mandible 4/1/2020: Melanoma, incomplete excision, MI > 20 per 10 hpf
- Left rostral mandibulectomy with submandibular lymph node extirpation 5/5/2020
  - Complete excision of melanoma with benign lymph node tissue
- Humanely euthanized after a brief illness with no overt metastasis 2025



Programmed Death Ligand-1 Pathway

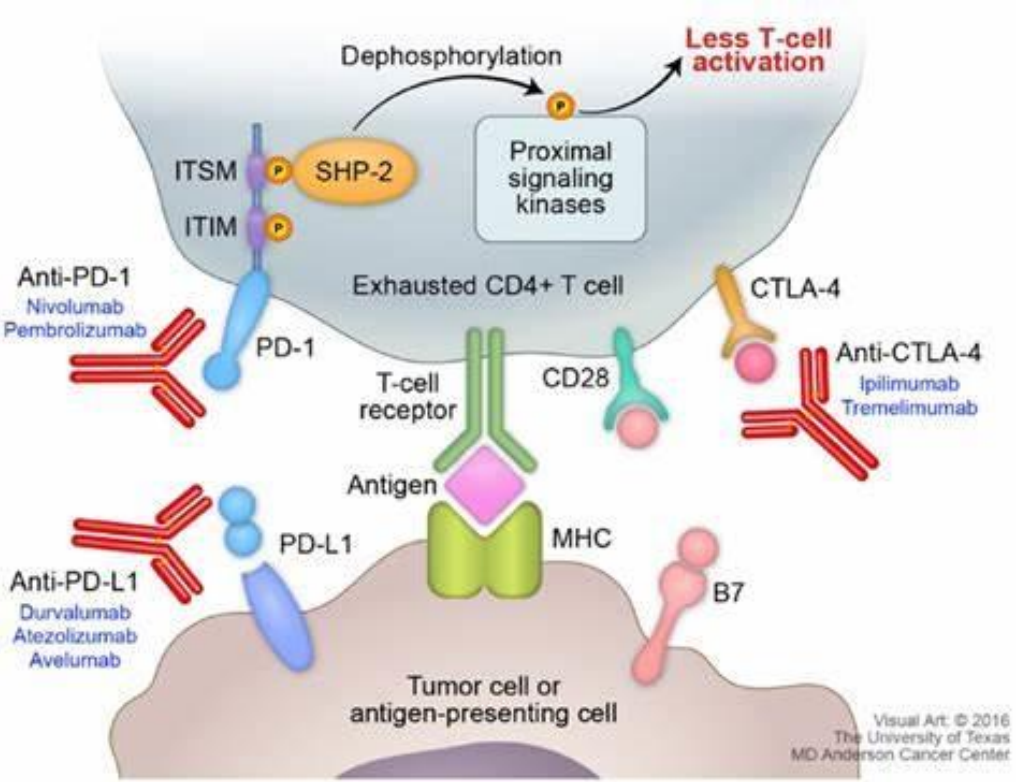

Chimeric antibodies

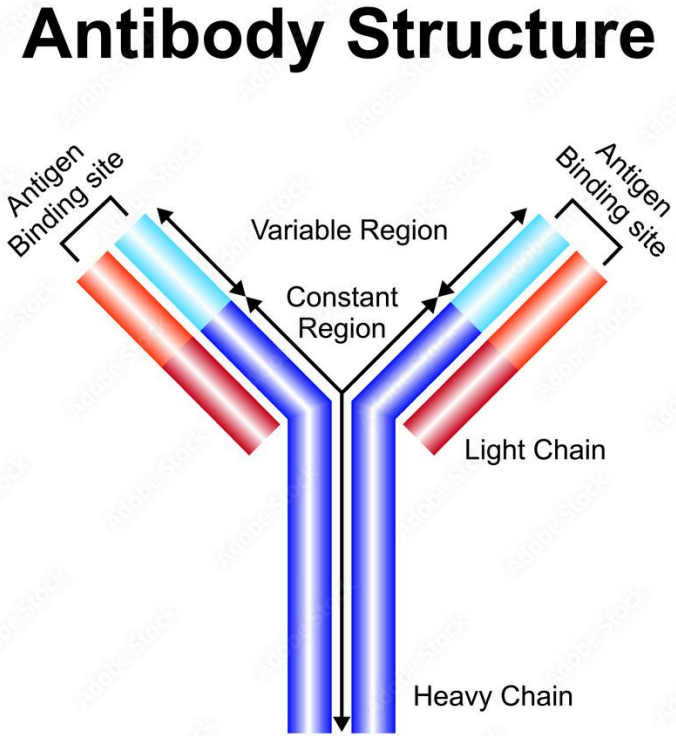

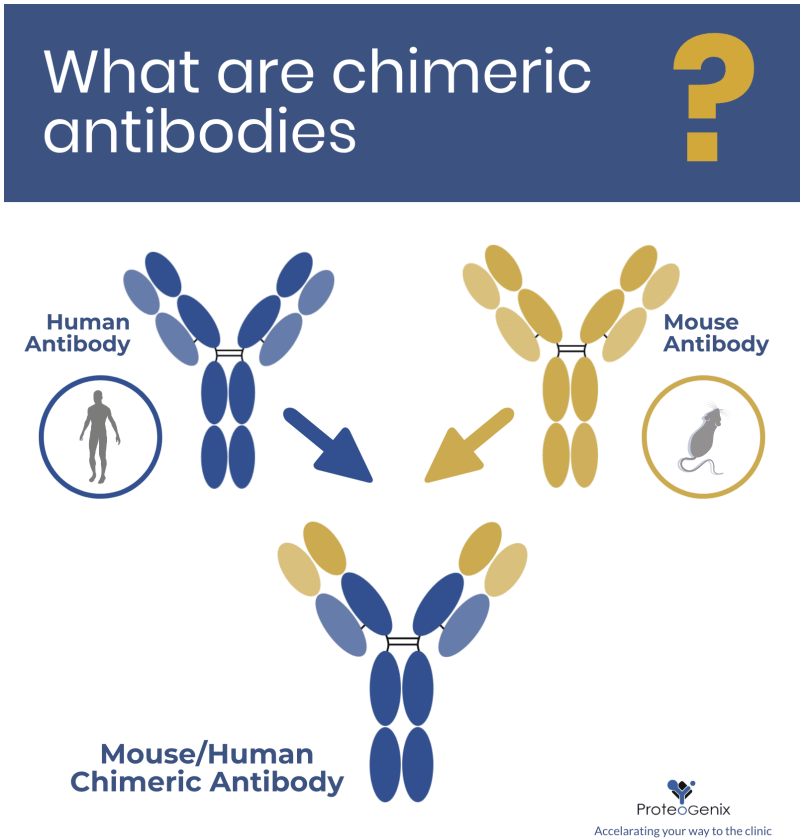

Adobe Stock | #497752247

PD-L1 immunohistochemistry for canine cancers and clinical benefit of anti-PD-L1 antibody in dogs with pulmonary metastatic oral malignant melanoma, Maekawa et al. 2021

- Canine chimeric anti-PD-L1 monoclonal antibody (c4G12)
- PD-L1 expression was detected in most canine malignant cancers including oral malignant melanoma, and survival was significantly longer in the c4G12 treatment group (median 143 days) when compared to a historical control group (n = 15, median 54 days)
- In dogs with measurable disease (n = 13), one dog (7.7%) experienced a complete response

Maekawa et al. 2021

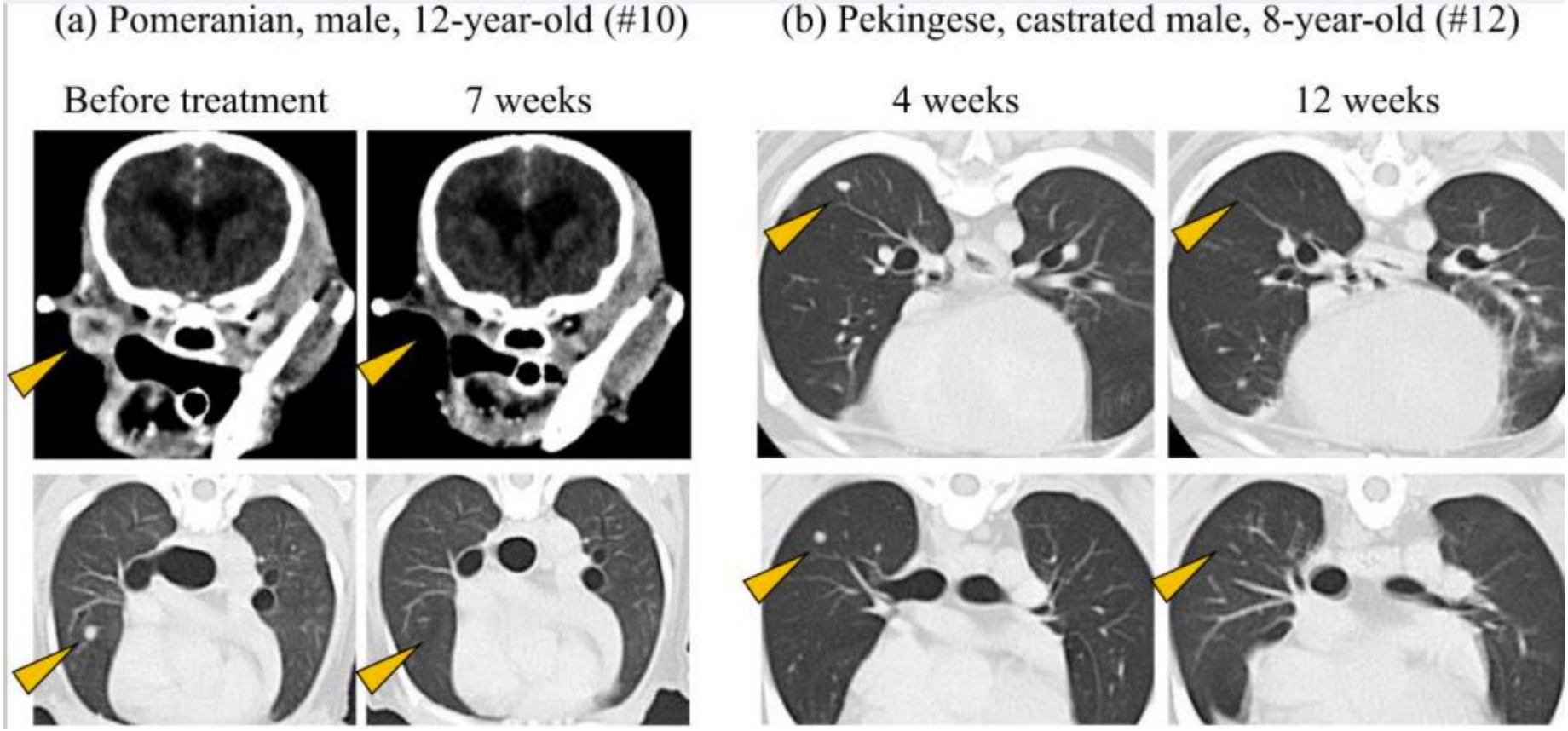

Gilvetmab

- A caninized monoclonal antibody against canine programmed cell death receptor-1
- Dogs with stage II and III melanomas
- Intravenous infusion of 4.5 mg/lb or 0.225 mL/lb (10 mg/kg or 0.5 mL/kg) body weight over at least 30 minutes every 2 weeks for up to 10 treatments
- Antihistamine (diphenhydramine 2 mg/kg) premedication orally 4 hours before or intramuscularly 15-30 minutes before is recommended
- A total of 25 dogs with stage II or III tumors were treated with up to a maximum of 12.7 mg/kg antibody every 14 days for up to 10 doses
  - A total of 5 dogs (20%) had an objective response with 2 dogs having a complete response and 3 dogs having a partial response
  - A total of 10 dogs (40%) had stable disease and 8 dogs (32%) had progressive disease

Summary of Adverse Reactions related to Melanoma Patients

Total number of animals: 25

Adverse Reaction	Any Grade AR	Grade 3-5 (severe to life threatening) AR
Lethargy/fatigue/general performance	6 (24.0%)	0 (0.0%)
Reduced appetite	4 (16.0%)	0 (0.0%)
Vomiting	4 (16.0%)	0 (0.0%)
Weight loss	4 (16.0%)	0 (0.0%)
Alkaline phosphatase	2 (8.0%)	0 (0.0%)
Anemia*	2 (8.0%)	0 (0.0%)
Nausea/ptyalism	2 (8.0%)	0 (0.0%)
Proteinuria	2 (8.0%)	0 (0.0%)
Leukemia*	1 (4.0%)	1 (4.0%)
Monocytosis*	1 (4.0%)	1 (4.0%)
Muscle weakness, generalized or specific area	1 (4.0%)	1 (4.0%)

Pseudoprogression

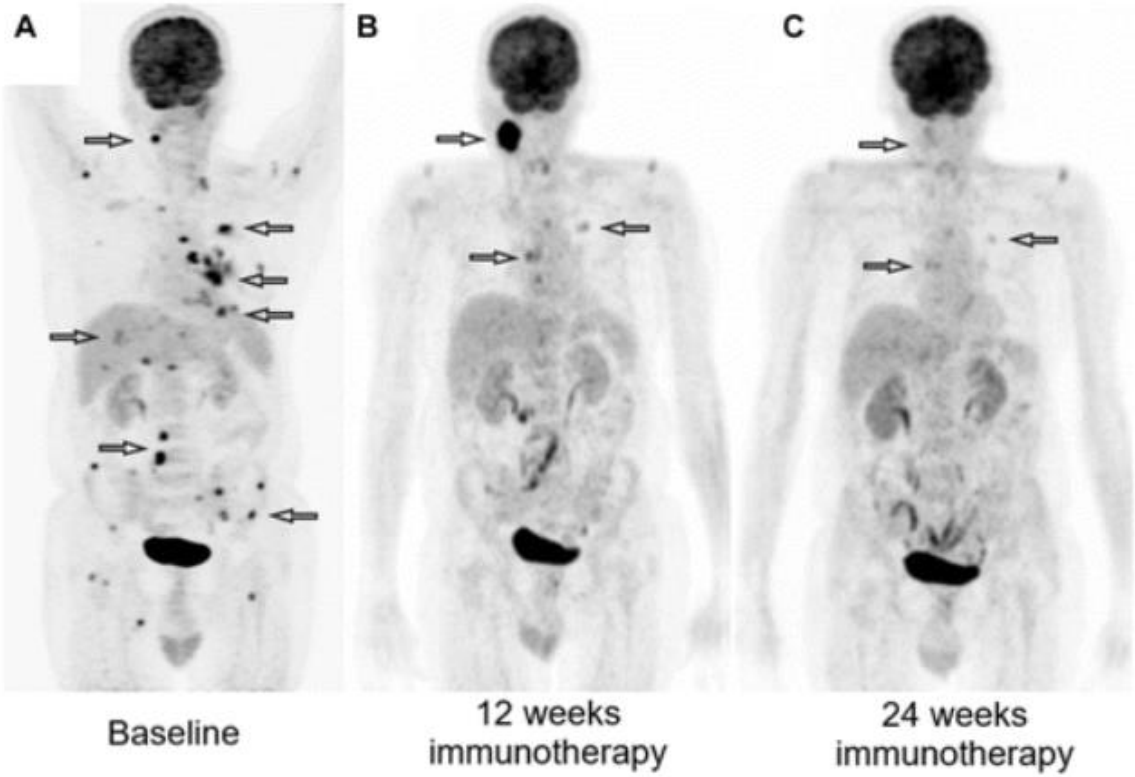

Pseudoprogression

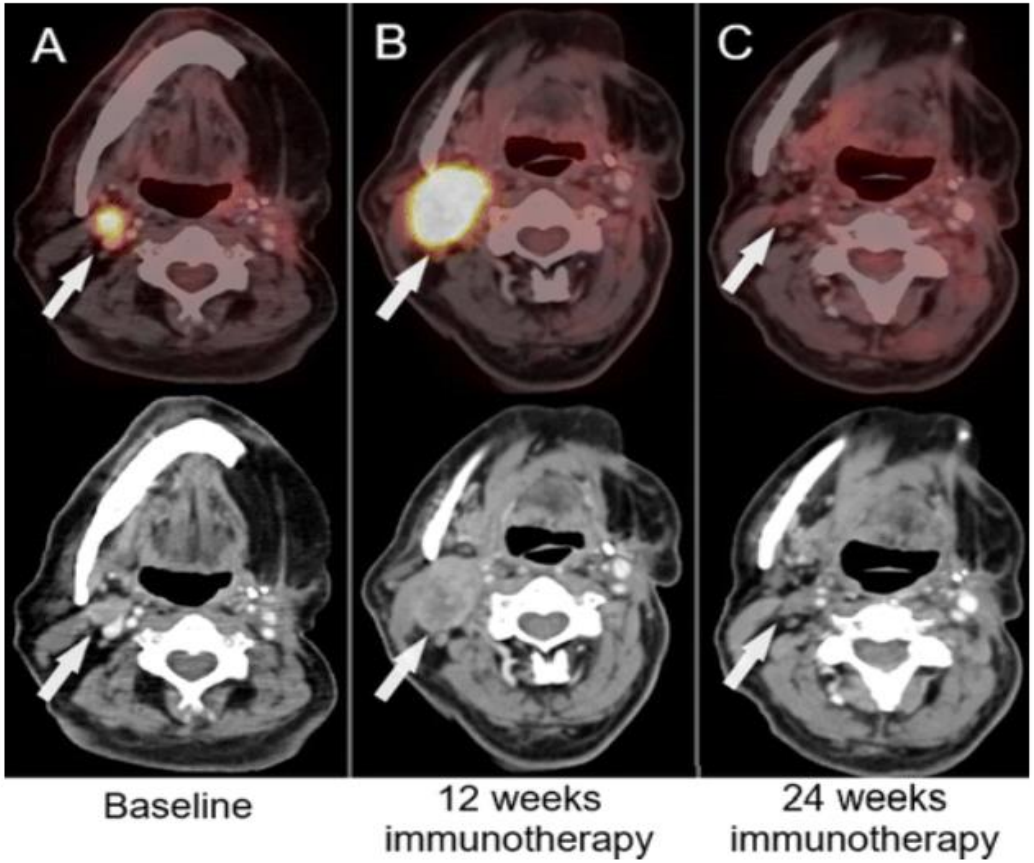

Case Example: None Yet



Expectations

- Accept the inevitability of disappointment the more Gilvetmab is administered
- Be hopeful for the identification of subsets of patients who will benefit from Gilvetmab
- Can we determine which patients will benefit and which patients will fail over time?



Questions





References

- Withrow, SJ, Vail DM, and Page RL: Small animal clinical oncology, *Elsevier* 5 (19): 321-334, 2013.
- Goldschmidt MH: Benign and malignant melanocytic neoplasms of domestic animals, *Am J Dermatopathol* 7 (Suppl): 203-212, 1985.
- Smith SH, Goldschmidt MH, McManus PM: A comparative review of melanocytic neoplasms, *Vet Pathol* 39(6): 651-678, 2002.
- Marino DJ, Matthiesen DT, Stefanacci D, et al.: Evaluation of dogs with digit masses: 117 cases (1981-1991), *J Am Vet Med Assoc* 207: 726-728, 1995.
- Macewen EG, Patnaik AK, Harvey HJ, et al.: Canine oral melanoma: comparison of surgery versus surgery plus Corynebacterium parvum, *Cancer Invest* 4(5): 397-402, 1986.
- Smedley RC, Lamoureux J, Sledge DG, et al.: Immunohistochemistry diagnosis of canine oral amelanotic melanocytic neoplasms, *Vet Pathol* 48(1): 32-40, 2011.
- Williams LE, Packer RA. Association between lymph node size and metastasis in dogs with oral malignant melanoma: 100 cases (1987-2001), *J Am Vet Med Assoc* 222(9): 1234-1236, 2003.
- Bateman KE, Catton PA, Pennock PW et al.: 0-7-21 radiation therapy for the treatment of canine oral melanoma, *J Vet Intern Med* 8(4): 267-272, 1994.
- Proulx DR, Ruslander DM, Dodge RK, et al.: A retrospective analysis of 140 dogs with oral melanoma treated with external beam radiation, *Vet Radiol Ultrasound* 44(3): 352-359, 2003.
- Murphy S, Hayes AM, Blackwood L, et al.: Oral malignant melanoma: the effect of coarse fractionated radiotherapy alone or with adjuvant carboplatin therapy, *Vet Comp Oncol* 3(4): 222-229, 2005.
- Grosenbaugh DA, Leard AT, Bergman PJ et al.: Safety and efficacy of a xenogeneic DNA vaccine encoding for human tyrosinase as adjunctive treatment for oral malignant melanoma in dogs following surgical excision of the primary tumor, *Am J Vet Res* 72(12): 1631-1638, 2011.
- Manley CA, Leibman NF, Wolchok JD et al: Xenogeneic murine tyrosinase DNA vaccine for malignant melanoma of the digit of dogs, *J Vet Intern Med* 25(1): 94-99, 2011.
- Dank G, Rassnick KM, Sokolovsky Y et al.: Use of adjuvant carboplatin for treatment of dogs with oral malignant melanoma following surgical excision, *Vet Comp Oncol* 12(1): 78-84, 2014.
- Maekawa N, Konnai S, Nishimura M et al.: PD-L1 immunohistochemistry for canine cancers and clinical benefit of anti-PD-L1 antibody in dogs with pulmonary metastatic oral malignant melanoma, *NPJ Precis Oncol* 5(1): 10, 2021.